

Antimicrobial Bone Graft Substitutes¹

Joseph C. Wenke, Steven J. Svoboda, Anthony A. Beardmore,
Darryl. B. Thomas, Terry G. Bice, Daniel E. Brooks

US Army Institute of Surgical Research
3400 Rawley E. Chambers Avenue
Fort Sam Houston, TX 78234-6315

Email: Joseph.Wenke@CEN.AMEDD.ARMY.MIL

ABSTRACT

Open fractures account for approximately 20% of all combat-related injuries in soldiers. Because of the severity of wounding mechanisms and high rates of wound infection, open fractures from combat pose greater problems to surgeons and result in higher morbidity than similar injuries suffered by civilians. Standard care for open fractures requires multiple procedures, including irrigation, débridement, stabilization, and antibiotic therapy. A commonly used method to provide local antibiotics through elution and to fill dead space is the application of polymethylmethacrylate (PMMA) combined with a broad-spectrum antibiotic, rolled into beads, and placed in the bone defect. Although effective for treating infection, these cement beads are not bioabsorbable and will eventually retard bone growth if not removed during a second surgical procedure. Yet a third procedure for bone autografting is often required for definitive treatment. Current standard care with multiple procedures and delayed definitive treatment results in high patient morbidity and increased cost of treatment. To evaluate potential alternatives to current standard care we have developed a large animal open fracture model in goats. Thus far we have tested different osteoconductive or osteoinductive bone graft substitutes impregnated with antibiotics to determine the ability of each product to reduce infection rates. All products have been as effective as standard care treatment in preventing infection in this contaminated bone defect model. Current research is evaluating the use of similar, but commercially available products that have been approved, or are pending approval, by the United States Food and Drug Administration. The use of antimicrobial bone graft substitutes may reduce morbidity, the number of surgical interventions, and associated medical costs for military personnel and civilians alike.

1.0 INTRODUCTION

Open fractures, defined as broken bone in communication with the environment, account for approximately 20% of all injuries sustained on the battlefield [1-3]. These fractures, which are frequently the result of high-energy impact, are difficult to manage because of segmental defects, neurovascular damage, or inadequate soft tissue coverage. In addition, associated bacterial contamination presents an enormous surgical challenge and considerable patient morbidity. Despite meticulous treatment, open fractures have high rates of delayed union and non-union, causing complications such as chronic osteomyelitis that can threaten the viability of the limb and even the life of the patient [4]. Bone defects typically require treatment with a bone graft to augment

¹ The opinions or assertions contained herein are the private views of the authors and are not to be construed as official or as reflecting the views of the Department of the Army or the Department of Defense.

Paper presented at the RTO HFM Symposium on "Combat Casualty Care in Ground Based Tactical Situations: Trauma Technology and Emergency Medical Procedures", held in St. Pete Beach, USA, 16-18 August 2004, and published in RTO-MP-HFM-109.

Antimicrobial Bone Graft Substitutes

fracture healing. However, a bone graft cannot be placed in a wound immediately following injury, due to wound contamination and the high risk of infection. The wound bed must first be thoroughly cleaned, and the patient placed on systemic antibiotics. In some instances, to treat severely contaminated wounds, a high concentration of antibiotics is mixed with polymethylmethacrylate (PMMA) bone cement to form small beads that are temporarily placed into the contaminated fracture site for periods as long as six weeks. The beads preserve soft-tissue tension and decrease the amount of dead space [5] while slowly eluting high levels of antibiotic into the surrounding environment; this level of medication would be toxic if delivered systemically [6]. After the wound is thoroughly cleaned, the beads are removed and, if necessary, definitive bone grafting is performed.

Despite clinical studies demonstrating the efficacy of this local antibiotic delivery technique, there are several disadvantages. Most importantly, PMMA is not biologic, necessitating a second surgical procedure for removal. Furthermore, since the beads are not osteoinductive, (i.e., cannot induce bone growth), definitive bone grafting and mature fracture healing cannot begin until the beads are removed. In addition, when autologous bone graft is used, harvest may result in significant morbidity due to blood loss, operative time, postoperative pain, and difficulty with ambulation [7]. The goal of our research is to find an all-in-one substitute for the current long and drawn out process of staged repair to reduce morbidity, shorten recovery time, and reduce cost. The ideal bone graft product should be osteoconductive, to provide a scaffold for bone growth, as well as osteoinductive. It should also be antimicrobial and available in unlimited supply.

We have tested two bone graft substitutes in animal studies—tobramycin-impregnated calcium sulfate pellets and tobramycin-impregnated calcium sulfate pellets combined with demineralized bone matrix (DBM)—that meet some of these criteria. Biodegradable antibiotic delivery systems have been used in Europe for many years with excellent clinical results [8, 9]. However, biodegradable products containing antibiotic delivery systems have not yet been approved for clinical use in the United States. In the United States only biodegradable products *without* antibiotics, such as calcium sulfate and calcium phosphate, have been approved by the FDA.

Calcium sulfate, which has been used since 1892 as a bone defect filler and is known to be osteoconductive [10], can be impregnated with an antibiotic. Demineralized bone matrix (DBM) is also commercially available, is osteoinductive, and has been shown to promote bone healing. Turner, Urban and Gitelis, using a canine model, showed that the combination of calcium sulfate pellets and DBM was more effective as a bone graft substitute than either component alone [11]. Additionally, they demonstrated that the combination was as effective as autogenous bone graft at six weeks following treatment. We speculated that the combination of tobramycin-impregnated sulfate pellets and DBM could be used as a local antibiotic delivery system that would be osteoinductive as well as osteoconductive.

We have teamed with industry and academia to use existing and emerging products and information to identify a better treatment for open fractures. In order to accomplish this goal, a large animal contaminated bone defect model has been developed to evaluate the effectiveness of various treatments in an ongoing series of experiments. We describe two completed studies that evaluated experimental treatments for reducing infection rates of open fractures. These treatments have the potential to reduce the number of surgeries, patient morbidity rates, total cost of the treatment, and to speed the soldier's return to duty.

2.0 METHODS AND MATERIALS

2.1 Experimental Design

We developed a large animal model (*vide infra*) to mimic a contaminated open fracture. Study I used this model to evaluate the effectiveness of OSTEASET T® (Wright Medical Technology, Arlington, TN), an antibiotic-impregnated calcium sulfate bone replacement material. Animals were divided into four groups: negative control, positive control, calcium sulfate, and experimental. The negative control group received no treatment. The positive control group received current standard care of PMMA beads impregnated with 4% tobramycin by product weight. The beads were prepared and rolled by hand in standard clinical fashion and placed in the metaphyseal defect. The calcium sulfate group received 15 pellets of the commercially available product OSTEASET® (Wright Medical Technology, Arlington, TN). The experimental group received 15 pellets of OSTEASET T®, which are calcium sulfate and 10% tobramycin by product weight. Study II evaluated the effectiveness of an antibiotic-impregnated calcium sulfate bone replacement material when combined with DBM; the combination of calcium sulfate and DBM has been shown to be effective in stimulating bone growth. Animals were again divided into four groups: negative control, positive control, DBM, and experimental. The negative and positive control groups received the same treatment as Study I. The DBM group received 2.5 ml of DBM (ALLOMATRIX™ injectable putty; Wright Medical, Arlington, Tennessee). The experimental group received 15 pellets of OSTEASET T® and 2.5 ml of DBM.

2.2 Surgical Technique

Adult male Spanish goats were used for our studies. A 2.5-cm longitudinal skin incision was made over the medial proximal metaphyseal region of the tibia centered at a point approximately 2 cm medial and 2 cm distal to the tibial tubercle. After elevating the periosteum with a periosteal elevator, a unicortical, 12-mm circular defect was produced with a coring reamer. Next, the bony defect was inoculated with an aliquot of bacteria (30 µl of solution with 10⁶ CFU/ml of *Staphylococcus aureus*). The bacterial strain used was American Type Culture Collection (ATCC) 29213, which was further modified by our institution to be resistant to streptomycin. Thirty µl of a 10⁶ CFU/ml solution of bacteria has been shown to be sufficient to cause infection in greater than 70% of non-treated animals without producing overwhelming sepsis [12].

2.3 Wound Grading System

The animals were followed daily for 21 days for clinical signs of infection. After the dressing was removed on postoperative day 4, three independent examiners graded each wound daily. The goat's treatment group was masked to the graders for the duration of the study. We used a clinical grading system established in a previous caprine study [12]. The condition of the wound was graded by the following criteria: a score of 0 was assigned for no signs of contamination; 1 for inflammation, swelling, or serous drainage without frank purulence; 2 for frank purulence at the wound site, or purulent discharge upon aspiration or incision and drainage. A score for each wound was calculated by adding the score from each of the three observers each day for 21 days. The clinical determination of infection was defined by a score of at least 5 on two consecutive days for a given wound. Hence, a wound had to exhibit two consecutive days of purulent drainage, as identified by at least two of the three examiners, to be considered infected.

2.4 Necropsy and Microbiologic Analysis

On postoperative day 21, the animals were euthanized and the treated hindlimb was disarticulated at the hip and radiographs were obtained. The bony defect was transected at its mid portion with a Gigli saw. Culture

swabs were obtained from the proximal and distal intramedullary canals. A number 5 surgical curette (0.5 g tissue) was used to harvest marrow and trabecular tissue from the canal.

The tissue and swab samples were sent for standard qualitative quantitative and microbiological analysis. Isolates were identified by routine microbiological procedures. Each *S. aureus* isolate was tested for streptomycin resistance to determine whether it was the same strain as the initial inoculation.

2.5 Outcome Measures

The outcome measure used to define the presence of deep wound infection was the recovery of the streptomycin resistant *S. aureus* strain ATCC 29213 from intramedullary cultures at 21 days. The threshold for infection was set at 10^4 CFU/g of marrow [12]. Cultures with bacteria present but less than 10^3 CFU/g marrow were considered contaminated. If the quantitative analysis identified between 10^3 and 10^4 CFU/g marrow of bacteria at final tissue culture, the clinical score was used to determine infection (i.e., the wound had to be considered infected by our clinical scoring criteria to receive definitive identification).

3.0 RESULTS

3.1 Study I

The primary determination of infection in this study and Study II was the recovery of the inoculated bacteria from the intramedullary cavity. *S. aureus*-R was found in the deep wounds in eleven of the twelve goats in the negative control group ($6.9 \times 10^7 \pm 4.0 \times 10^7$ CFU/g) and in all twelve wounds in the calcium sulfate group ($2.2 \times 10^8 \pm 1.1 \times 10^7$ CFU/g). No *S. aureus*-R was recovered in any of the bony defects of the goats in the positive control and experimental groups. The amount of bacteria recovered from the intramedullary cavity differed between the tobramycin-treated group and the group that was not treated ($p < 0.002$). The carrier group clinical infection rate was higher than the positive control and treatment groups ($p < 0.02$). In addition, gross pathologic and radiographic evaluation confirmed a difference between the groups that were and were not treated with tobramycin. There was purulent replacement of marrow and trabecular bone in the negative control and calcium sulfate groups, whereas the positive control and treatment groups appeared to have normal marrow and trabecular bone. The radiographic evaluation of the negative control and calcium sulfate groups further suggested infection by revealing evidence of periosteal new bone formation that produced involucra in all of the infected bony defects. The bony defects in the two groups that were treated with antibiotic appeared normal.

3.2 Study II

S. aureus-R was found in the bony defects in six of seven goats in the negative control group ($2.2 \times 10^8 \pm 1.2 \times 10^8$ CFU/g) and in seven out of eight goats in the DBM group ($1.3 \times 10^8 \pm 8.1 \times 10^7$ CFU/g). No *S. aureus*-R was recovered in any of the deep wounds of the goats in the positive control and experimental groups. The amount of bacteria recovered from the deep wounds differed between the groups that were treated with tobramycin and those that were not treated ($p < 0.02$). The DBM group had a significantly higher rate of clinical infections than did the experimental, positive control, and negative control groups ($p = 0.0058, 0.01, \text{ and } 0.0187$, respectively).

The gross pathologic and radiographic evaluation results were similar to Study I. The radiographs revealed pronounced periosteal reaction in the groups that were not tobramycin treated. The radiographs from the

positive control and experimental groups qualitatively displayed less periosteal reaction than the other groups. Gross pathological analysis revealed purulent replacement of marrow and trabecular bone in the negative control and DBM groups. The tobramycin treated groups appeared to have normal marrow and trabecular bone (fig. 1).

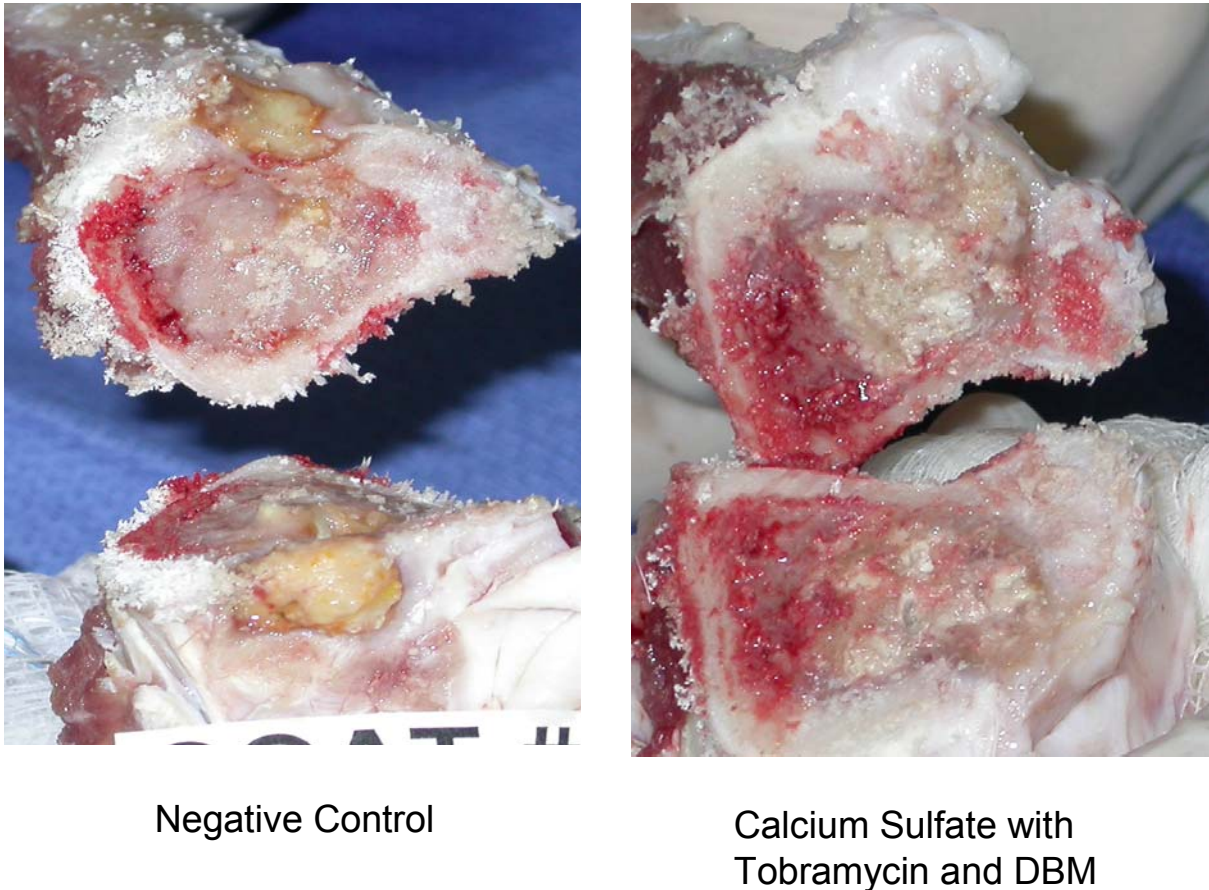


Figure 1: Gross anatomy samples from negative control group (left) and experimental group (right). The negative control group, which received no treatment showed purulent replacement of bone marrow and trabecular bone. The experimental group in which defect was treated with antibiotic-impregnated calcium sulfate bone replacement material combined with demineralized bone matrix (DBM) showed normal bone marrow and trabecular bone.

4.0 DISCUSSION

These studies demonstrate that an antibiotic-impregnated bone graft substitute can be used effectively in a contaminated fracture model. We feel that this is a valid model to evaluate a product's ability to prevent an infection in an open fracture. In our tibial defect model, similar to open fractures in humans, bacteria have access to the intramedullary space. Bacteria are able to colonize this wound if it is left untreated and the wound becomes infected. However, in this model, because wounds become infected without causing overwhelming sepsis, the goats are not subjected to excessive stress and do not have to be euthanized prior to

Antimicrobial Bone Graft Substitutes

the completion of the study. In addition, the unicortical defect does not require stabilization, and the goats are able to ambulate within hours of surgery.

Standard care often dictates a high level dose of antibiotic-impregnated PMMA that would be toxic if delivered systemically. PMMA beads “hold the space” by preventing the formation of fibrous tissue while the local dose of antibiotic is eluted. This procedure is generally the first stage of a procedure requiring a second operation that then leaves a bone void. An autograft or allograft is routinely placed in the void to stimulate bone growth. Calcium sulfate pellets with tobramycin as used in our study act similarly to PMMA beads and fill the dead space and prevent the formation of fibrous tissue while eluting a local dose of antibiotic. Calcium sulfate, however, is resorbable, which could prevent the need for a second operation to remove the substance that is not biologic. Unfortunately, calcium sulfate is only osteoconductive, and in a canine model it takes 24 weeks for calcium sulfate pellets to stimulate as much bone as autogenous bone graft [11]. When osteoconductive calcium sulfate pellets and osteoinductive DBM are combined the resulting product can stimulate as much bone growth as autograft in just 6 weeks in the same model [11]. Theoretically, by adding tobramycin, the combination should be antimicrobial as well, but this combination had yet to be challenged in a contaminated fracture model.

Our preliminary studies provide the groundwork for future studies. In the contaminated fracture model used in the second study, tobramycin-impregnated calcium sulfate pellets and DBM combination was not significantly different from tobramycin-impregnated cement beads in preventing establishment of *S. aureus* infection. However, use of the antibacterial calcium sulfate pellet and DBM combination could decrease the morbidity of open fractures by eliminating the need for surgical bead removal and by reducing the need of an autograft. Combining this calcium sulfate product with DBM could potentially accelerate bone formation. Reducing multiple procedures to a single-stage treatment will also reduce the overall risk to the patient.

5.0 SUMMARY

The current standard of care for battlefield open fractures is not acceptable, as evidenced by the high rates of infection and nonunion. The treatments that we have evaluated were as effective as antibiotic impregnated cement beads and they have the potential to reduce the number of surgeries, morbidity, and return to duty time because they are resorbable and promote bone growth. Currently, we are testing commercially available products that have been approved, or are pending approval, by the United States Food and Drug Administration. These products will reduce the number of procedures that the surgeon must perform to treat the fracture and are closer to finding a definitive treatment. Future studies will focus on the effects of products on bone healing and will evaluate the effectiveness of tobramycin in preventing infection when the wound is contaminated with gram negative bacteria (*Pseudomonas aeruginosa*).

6.0 REFERENCES

1. Mabry RL, Holcomb JB, Baker AM, et al. United States Army Rangers in Somalia: an analysis of combat casualties on an urban battlefield. *J Trauma*. Sep 2000;49(3):515-528; discussion 528-519.
2. McBride JT, Marjorie MH, Hannon JP, Hoxie SW, Rodkey WG. *Report and Medical Analyses of Personnel Injury from Operation "Just Cause"*. 1991.
3. Uhorchak JM, Rodkey WG, Hunt MM, Hoxie SW. *Casualty data assessment team operation desert storm*. 1992.
4. Maricevic A, Erceg M. War injuries to the extremities. *Military Med*. 1997;162:808-811.
5. Ueng SWN, Wei F-C, Shih C-H. Management of femoral diaphyseal infected non-union with antibiotic beads local therapy, external skeletal fixation, and staged bone grafting. *J Trauma*. 1999;46(1):97-103.
6. Goodell JA, Flick AB, Hebert JC, Howe JG. Preparation and release characteristics of tobramycin-impregnated polymethylmethacrylate beads. *Am J Hosp Pharm*. 1986;43(6):1454-1461.
7. Younger EM, Chapman MW. Morbidity at bone graft donor sites. *J Orthop Trauma*. 1989;231:239-271.
8. Calhoun JH, Mader JT. Treatment of osteomyelitis with a biodegradable antibiotic implant. *Clin Orthop*. 1997;341:206-214.
9. Sasmor MT, Morain WD, Balestrero LM. Investigation of a biodegradable, implantable antibiotic delivery system on rate of wound infection. *Ann Plast Surg*. 1993;30:525-530.
10. Kelly CM, Wilkins RM, Gitelis S, Hartjen C, Watson JT, Kim PT. The use of a surgical grade calcium sulfate as a bone graft substitute: results of a multicenter trial. *Clin Orthop*. Jan 2001(382):42-50.
11. Turner TM, Urban RM, Gitelis S, Kuo KN, Anderson GBJ. Radiographic and histologic assessment of calcium sulfate in experimental animal models and clinical use as a resorbable bone-graft substitute, a bone-graft expander, and a method for local antibiotic delivery. *J Bone Joint Surg [Am]*. 2001;83-A(Suppl. 2, Part 1):8-18.
12. DeJong ES, DeBerardino TM, Brooks D, E. Antimicrobial efficacy of external fixator pins coated with a lipid stabilized hydroxyapatite/chlorhexidine complex to prevent pin tract infection in a goat model. *J Orthop Trauma*. 2001;50(6):1008-1014.

